

## Genital Piercings: Diagnostic and Therapeutic Implications for Urologists

Thomas Nelius, Myrna L. Armstrong, Katherine Rinard, Cathy Young, LaMicha Hogan, and Elayne Angel

<b>OBJECTIVE</b>	To provide quantitative and qualitative data that will assist evidence-based decision making for men and women with genital piercings (GP) when they present to urologists in ambulatory clinics or office settings. Currently many persons with GP seek nonmedical advice.
<b>MATERIALS AND METHODS</b>	A comprehensive 35-year (1975-2010) longitudinal electronic literature search (MEDLINE, EMBASE, CINAHL, OVID) was conducted for all relevant articles discussing GP.
<b>RESULTS</b>	Authors of general body art literature tended to project many GP complications with potential statements of concern, drawing in overall piercings problems; then the information was further replicated. Few studies regarding GP clinical implications were located and more GP assumptions were noted. Only 17 cases, over 17 years, describe specific complications in the peer-reviewed literature, mainly from international sources (75%), and mostly with "Prince Albert" piercings (65%). Three cross-sectional studies provided further self-reported data.
<b>CONCLUSION</b>	Persons with GP still remain a hidden variable so no baseline figures assess the overall GP picture, but this review did gather more evidence about GP wearers and should stimulate further research, rather than collectively projecting general body piercing information onto those with GP. With an increase in GP, urologists need to know the specific differences, medical implications, significant short- and long-term health risks, and patients concerns to treat and counsel patients in a culturally sensitive manner. Targeted educational strategies should be developed. Considering the amount of body modification, including GP, better legislation for public safety is overdue. UROLOGY 78: 998–1008, 2011. © 2011 Elsevier Inc.

Body piercings are fistula-like tracts<sup>1</sup> developed under the skin with a large bore needle to create an opening into the anatomical region for decorative ornaments, such as jewelry.<sup>2-4</sup> What makes this purposeful man-made phenomenon so sociologically interesting is that virtually every global culture has some form of piercing,<sup>1</sup> no external anatomical site has escaped jewelry ornamentation,<sup>5</sup> and humans have been participating in various forms of body modification for thousands of years.<sup>3,4,6-8</sup> In the mid-1990s general body piercing started appearing in the US health care literature.<sup>4</sup> First came the visible face, ears, and eyebrow areas, and then the semi-visible tongue and navel sites.

Genital piercings (GP) are part of the third category of body piercings (intimate).<sup>9-13</sup> Those with GP have self-reported—especially men with genital piercings (MGP)—that they often seek nonmedical advice (Internet and/or piercers)<sup>2,6,11-13</sup> for complications because they fear rid-

icule, lack confidence in clinician knowledge, and/or are automatically told to remove the piercing. Yet, more MGP and women with genital piercings (WGP) will present to urologists for specific jewelry insertion complications, as well as for holistic examinations for other medical situations, and the GP will become apparent.<sup>11</sup> This article provides clinicians with a synopsis of the literature to date about MGP and WGP for evidence-based decision making in ambulatory clinics and office settings.

### MATERIAL AND METHODS

A comprehensive longitudinal electronic MEDLINE, EMBASE, CINAHL and OVID search about GP was conducted between January 1975 and December 2010. Applicable medical information was sought in specific GP articles, as well as general body art publications; reference lists from relevant articles were also searched. National and international publications written in any language were included, but the abstract had to be in English.

### RESULTS

This GP search resulted in 153 publications. Most articles (n = 76) combined discussion about tattoos and body piercing, another 39 concentrated on each general

From Texas Tech University Health Sciences Center Department of Urology, School of Medicine, Lubbock, TX; Texas Tech University Health Sciences Center Anita Thigpen Perry School of Nursing, Lubbock, TX; Family Nurse Practitioner, Bursleson, TX; and Arkansas State University, Jonesboro, AR

Reprint requests: Dr. Myrna Armstrong, Texas Tech University Health Sciences Center, Anita Thigpen Perry School of Nursing, Lubbock, TX 79430. E-mail: myrna.armstrong@ttuhsc.edu.

Submitted: April 1, 2011, accepted (with revisions): May 28, 2011

body piercing site and its associated complications, and 38 specifically presented GP information. An excellent GP historical and medical guide was published in 2003.<sup>6</sup> Few studies were present, with most of the information extrapolated from case histories.<sup>13</sup>

### Medical Implications for Urologists

**Body Piercings Legislative Mandates.** In the US no federal mandates exist for body art, though most body piercing regulations apply to any puncture site, with specific regulations virtually nonexistent for GP.<sup>4,6</sup> Overall, state regulations regarding sanitation practices, artist training, and infection control vary substantially, yet more than 40 states and several municipalities have some regulations. Equally important for public safety is regulatory enforcement.

Internationally, UK authors<sup>6,8,10,14</sup> frequently discuss the 1985 Female Circumcision Act, which prohibits cutting, piercing, or otherwise modifying female genitalia; some believe this regulation inhibits WGP, whereas others are more realistic that GP on women have been performed in that country.<sup>10</sup> The World Health Organization<sup>6</sup> has definitions for body modifications, and some countries (ie, Canada, Iceland, Italy, Mexico, the Netherlands, New Zealand, Peru, Spain, Ireland, and Scotland)<sup>4</sup> have regulations, whereas others (ie, Australia, Korea, and Venezuela) do not. Again, no specific GP regulations are included.

**Prevalence.** Actual global-wide general body piercing prevalence tends to be elusive—different from tattooing—because the wearer can remove the piercing at any time, with little or no residual effect.<sup>5,15</sup> Eliminating for ear lobe piercings, current national reports cite 23-45% of the millennials (18-29-year-olds) with general body piercings and 9-20% of the 30-45-year-olds (Generation X).<sup>4,16,17</sup> More women (35%) wear general piercings than men (11%),<sup>4,16,18</sup> and almost one third of those with general body piercings admit that the piercings were self-inflicted.<sup>17</sup>

Most national and international reports<sup>3,15,18</sup> cite a 1-3% GP prevalence, with more MGP than WGP, probably because men have more anatomical tissue able to be pierced.<sup>6</sup> One national dataset found 10%,<sup>17</sup> and a cross-sectional report of body art customers<sup>7,19</sup> reported 28% with GP. Recent college studies conducted at the same university reflected a GP increase from 2-3% in one year.<sup>15</sup> Self-inflicted GP are rare, although 4 international situations were cited: an attempted self-testicular piercing,<sup>20</sup> actual penis piercings,<sup>21-22</sup> and a self-applied ball bearing ring (diameter 40 mm) from a truck,<sup>23</sup> around the whole scrotum.

**Procedural Technique.** The actual procedural technique for GP is similar to general body piercing, but there should be an increased competency level of the piercer. Specific genital piercer expertise should be not only in their knowledge of anatomical structures, but also in


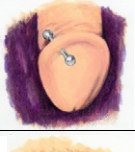


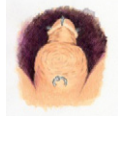
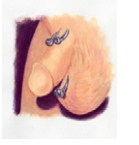

their preparation time for actual piercing placement to desired outcome, and the appropriate jewelry gauge (thickness).<sup>7</sup> The site is marked with ink, the skin site is held taut, and, depending on placement, a receiving tube or a forceps supports the tissue to improve accuracy and minimize tissue damage. Then a 12-16-gauge hollow needle<sup>1,7,12</sup> punctures the skin. Applicable jewelry (heavy gauge surgical grade steel, niobium, or titanium) is then quickly threaded through the site. Note: Piercing jewelry is “gauged” differently than medical sizing; those with GP typically wear thicker jewelry (10-14 ga) compared with earlobe wires (18-20 ga), which, if “caught or tugged on,” could quickly “slice” the genital tissue.<sup>1,7</sup> Healing time varies with GP (Fig. 1), with effective skin epithelialization for a patent tract taking up to a year.<sup>4,7</sup>

**Basic Site Care.** Once the skin is pierced there always is a potential portal of pathogen entry so judicious site care is essential. A small to moderate amount of bleeding from 1-3 days, especially in MGP, is expected with a freshly created GP.<sup>7</sup> Specific concerns for effective procedural healing after GP include avoiding unprotected intercourse, swimming pools, and Jacuzzis for at least 2-4 weeks.<sup>7</sup> Consistent protective wear is important<sup>1,4,6</sup> and extra large condoms are available to accommodate the different types of GP and the variety of heavy genital jewelry.<sup>7</sup>

**Types of Genital Piercings.** Figure 1 provides anatomical illustrations of the common types of GP worn by men<sup>2</sup> and women,<sup>11</sup> yet the urologist should be forewarned that creativity is not unusual. For men, the penis is the usual location for the jewelry. The Prince Albert is the most common with the urethral jewelry insertion but it can also produce urinary flow changes.<sup>2,6,8,13</sup> For women, the amount of anatomical tissue, as well as the “expected physiologic changes related to sexual arousal” often determine the placement, such as the clitoral area and/or labia majora/minora<sup>7</sup>; WGP often refer to their “clit” piercing, but the actual placement is more commonly in the surrounding areas of the clitoris, instead of a rare piercing directly into the sensitive clitoral glands.<sup>7,11</sup> Although many illustrations demonstrate the horizontal clitoral hood piercing for women, the vertical clitoral hood is actually the most popular because it produces more anatomical stimulation and less “clothing drag.”<sup>7,11</sup>

**Psychosocial Perspectives.** Contrary to most assumptions, body art, including GP, are not done as a rebellious act.<sup>2,4,8,11,13,15</sup> In the last 10 years, 3 different cross-sectional studies with more than 800 national and international GP participants, have provided further and similar data about their GP experiences,<sup>2,11,13</sup> and these findings have challenged several published assumptions (Table 1) about people with GP.

**Demographics.** In contrast to general body piercing wearers, the average GP respondent is older ( $\geq 30$  years




Figure	Description
Male Genital Piercings	
	<b>Ampallang (“crossbar”) &amp; Apadravya:</b> Neither are common. <b>Ampallang</b> is placed horizontally, through the center of the head of the penis; it may pass through the urethra or above it. Healing time 6-9 months or longer. The <b>Apadravya</b> is placed vertically through the penis head and passes through the urethra for faster healing. Both produce intermittent bleeding following procedure.
	<b>Dydoe:</b> Not so popular. Involves single or multiple bars through both sides of the glans rim, usually on circumcised men. Origin might be Jewish. Healing time 3-4 months or longer.
	<b>Foreskin:</b> Often done on both sides of the foreskin of uncircumcised men with small gauze rings that can be connected, deliberately making intercourse difficult. Healing time 2-3 months or longer.
	<b>Frenum or Frenum Ladder:</b> Easy to perform, popular, and not as painful. Placed on underside of penis, or a large ring can be placed around the head of the penis in the groove around the glans. The <b>Frenum Ladder</b> is a variation where multiple barbell piercings are placed on top, sides, or underside of the penis shaft. Also called <b>Jacob’s Ladder</b> . Healing time 3-4 months or longer.
	<b>Guiche:</b> Done between the scrotum and anus, behind the testes, usually corresponds above the inseam of pants. Healing time 3-4 months or longer
	<b>Hafda &amp; Pubic Piercing:</b> <b>Pubic</b> is placed at the juncture of the penis shaft and pubic mound; it does not pierce the penis, sometimes nicknamed “Rhinoceros Horn”, whereas the <b>Hafada</b> does not penetrate the scrotal sac, but is placed on the scrotum. It is not considered painful and is more decorative. Actual piercing is placed somewhere the scrotum and penis. Healing time 3-4 months or longer.
	<b>Prince Albert:</b> Most common male GP, jewelry is inserted through the external urethra and out the juncture of the glans and shaft. Easy to pierce and heal. Healing time is 1-2 months or longer. Is said to “offer intense urethral stimulation during intercourse.” <b>Reverse Prince Albert</b> exits the dorsum of the penis.

**Figure 1.** Common types of genital piercings (GP) worn by men and women.

of age),<sup>2,11,13,15</sup> in good health, not ethnically diverse, possesses some college education, and likes and often wears other types of body art (tattoos/general body piercings); they also report some depression.<sup>2,11,15</sup> GP wearers, as general piercing wearers, readily admit to being significant risk takers and seeking new experiences, but the decision to get a GP is more deliberate (>1 year) than general pierced wearers (<1 year). College WGP had significantly increased self-esteem issues, cigarette use, suicide attempts, and hiding of food, when eating in

women with eating disorders.<sup>15</sup> A multitude of occupations and physical activities were cited as providing few physical limitation evidence once the GP was obtained.<sup>2,11,13</sup> One wearer said, “If they had interfered with my daily routine I would not have obtained nor would I [have] kept them.”<sup>11</sup>

**Motivation.** Misconceptions, such as self-harm or sexual deviance,<sup>8</sup> have been listed for GP motivation, but in 5 GP studies<sup>2,11,13,15,19</sup> similar outcomes for genital pierc-

Female Genital Piercings	
	<b>Vertical Clitoral Hood:</b> Most popular piercing for women, quick & easy to heal placed above the clitoris not through it, the jewelry rests under the prepuce and produces increased sexual stimulation; <b>Labia Majora:</b> often placed on both sides or a ladder effect, mostly for aesthetics; <b>Fouchette</b> (French for “little fork”): similar to male guiche, positioned between back of vagina and anus. Procedure tricky, needs excellent hygiene.
	<b>Horizontal Clitoral Hood:</b> jewelry traverses the hood tissue above clitoris. Aesthetically appealing but does not produce much sexual stimulation; <b>Labia Minora;</b> quick & easy to heal, either single or multiple rings.
	Three major types of piercing jewelry for GP. Placement dictates the gauge of the jewelry.

Illustrations by Larry Starr, Senior Design Specialist: Texas Tech University Health Sciences Center.

Figure 1. Continued

ings have included “helped improve and express myself sexually” and “helped me feel unique.”

**Blood Donations.** A historical concern of epidemiologically links to hepatitis risks in the US and Canada created blood donation deferment for at least 12 months post-procurement among those with body art. In 2005, Canada began to permit blood donations after 6 months with no evidence for hepatitis B or C virus (HBV or HCV).<sup>24</sup> Nationally, states with studio standards and donors with no visible body art infections have no waiting period.

**Sexual Activity and Sexually Transmitted Infections.** GP wearers have been frequently assumed to have high sexually transmitted infection (STI) rates, hyperactive sexual activities, and nontraditional sexual orientation.<sup>8,25-27</sup> Although the ages of first-time sexual intercourse for WGP and MGP<sup>2,11,13</sup> have been significantly younger (14-16 years) than the national average (16.9 males/17.4 females),<sup>28</sup> few STIs, no HIV, and frequent monogamous relationships. Many of these relationships were heterosexual and some reported having children. Another study comparing pierced and nonpierced English women<sup>29</sup> found no relationship between those with GP and socioeconomic class, multiple partners, or the presence of STI.

**Women’s Health Issues With Genital Piercings.** In addition to providing sexual satisfaction,<sup>11,13,29,30</sup> many WGP have stressed how their GP have become a normal, meaningful part of their life.<sup>7,8,11,19</sup> No hormonal changes (Table 1) during menstruation or pregnancy related to healing time, maintenance, rejection risk, major medical illness, impotence, or sterility were cited.<sup>11,13</sup>

**Reclaiming the Body.** Significant abuse and rape have been evident in WGP; more than half reported some type of abuse and one third experienced forced sexual activity against their will.<sup>11,13</sup> The presence or the act of getting the GP seems to help them take control of (or reclaim) their body after these violations.<sup>3,11,15</sup>

**Pregnancy.** To date, no specific reports of delivery complications with GP have been located.<sup>31</sup> In one study, 25 WGP subjects discussed their pregnancies (n = 37) and more than half had not removed their jewelry for their deliveries or incurred any medical complications.<sup>11</sup>

**Diagnostic Procedures.** Although vaginal examinations, catheterizations, and radiologic procedures could be required for urinary system treatment on those with GPs, alternative methodologies have been suggested rather than routinely “clearing out the work area.”<sup>11</sup> With consideration of the anatomical structures involved and realistically working with the patient, smaller-sized urinary catheters can bypass most piercings, simple radiographs are not affected, effective radiological history-taking should eliminate magnetic field problems of an magnetic resonance imaging scan, and the GP could be taped, similarly as important rings, for surgery.<sup>11</sup> One cautionary note: Electrocautery equipment should not physically touch the jewelry.<sup>32</sup>

**Jewelry Removal.** All piercing wearers are very concerned with removing their jewelry because the channel can shrink or close quickly, and this holds true especially for those with GP. In addition, the location and size of the jewelry in GP can create a difficult removal process

**Table 1.** Potential concerns and uncited statements about those with GP

Year	Reference	Statement
<b>Males</b>		
2000	Cartwright <sup>34</sup>	"Sites are prone to infection due to the dark, moist environment and tight, restrictive clothing. Potential for impotence, female circumcision."
2001	Stewart <sup>9</sup>	"Scrotal piercings are associated with high rates of infection resulting from fecal soiling, moisture, and the constant irritation caused by walking."
2003	Stirn <sup>3</sup>	Ampallang; if cavernosum is hit by mistake, bleeding can be very hard to stop, loss of erection may follow.
2005	Meltzer <sup>5</sup>	Frictional irritation
2006	Braverman <sup>35</sup>	Scrotal piercings are particularly prone to infections.
2007	Waugh <sup>36</sup>	"GP is noted to have caused urinary tract infections. . . If too tight or too small a ring is inserted into the penis, it is likely to cause complications during an erection."
2007	Beers et al <sup>37</sup>	Prostatitis and testicular infections may also result from ascending infection of the testes after scrotal piercing.
2008	Kaatz <sup>38</sup>	Wound healing may . . . be protracted even longer by frequent bicycle rides. Severe acute complications are injuries of bigger blood vessels or nerves and especially severe local and systemic infections. Male infertility can result after piercing via ascending infections of the prostate or infections of the testes in scrotal piercings.
<b>Women</b>		
1999	Miller and Endenholm <sup>30</sup>	Tetanus . . . and scarring are possible complications.
2000	Christensen et al <sup>39</sup>	"Hormonal changes during the menstrual cycle and pregnancy affect healing time, maintenance, risk of rejection and infection."
2001	Stewart <sup>9</sup>	"Like all pierced sites, the clitoris is vulnerable to infection, allergic reaction, and fibrosis, which can literally ruin a woman's sex life."
2003	Stirn <sup>3</sup>	Guiche: sitting and riding bicycle may be painful
2005	Milner et al <sup>19</sup>	Inform patients of the obvious health risks associated with body piercings, such as infection and viral hepatitis as well as the possibility of streptococcal toxic shock syndrome associated with piercing mucosal surfaces.
2006	Braverman <sup>35</sup>	The clitoris is at risk for allergic reaction, infection, and fibrosis; piercing behind the clitoris is particularly dangerous because of possible compromise to blood flow.
2007	Leman and Plattner <sup>40</sup>	Keloid formation has been seen in clitoral piercings. Mentions severe laceration risk during labor and delivery.
2007	Beers et al <sup>37</sup>	Pelvic inflammatory disease is sometimes seen in genital piercing because of an ascending infection from the vagina or cervix into the uterus and adnexa.
2008	Van der Meer et al <sup>10</sup>	Re "Albertina, while sexually stimulating, there is a risk of cutting out during intercourse." Re "Christina infection rate high due to friction with clothing." Re "major minora, high tendency of rejection and easily aggravated by tight clothing and sweat." Additional complication: "endocarditis"
2008	Kaatz <sup>38</sup>	Piercing of the female genitalia may cause inflammatory pelvic bowel disease, which might be followed by infertility. The intended effort of better sexual stimulation or increased sensitivity is often missed, instead of which numbness or soreness result.

without ring-expanding fliers.<sup>1,7,32</sup> For a localized cellulitis, avoid removing the GP and instead institute warm compresses, frequent cleansing, and a topical antibacterial ointment, because the jewelry prevents abscess formation and facilitates a drainage channel.<sup>4,6,12,32</sup> If there is no resolution within 5-7 days, then jewelry removal is recommended (gynecologic examination position [lithotomy] best for WGP),<sup>32</sup> with surgical incision/drainage and appropriate intravenous antibiotic therapy.

Ask the patient to remove the jewelry for elective activities. Jewelry removal for short procedures (<1 hour) are not usually problematic, but even established clitoral hood and outer labia piercings close very quickly, making reinsertion difficult and sometimes impossible so

nonmetallic sterile intravenous tubing or suture are assistive. In one study, only a small percentage of clinicians were able to remove piercings properly from the body,<sup>14,33</sup> so knowledge of the basic jewelry types and removal techniques are important in urgent or emergent care. Extensive soft tissue skin damage from piercing site trauma can result in further infectious risks when ring or bolt cutters are used for removal; this technique also proves very difficult with the heavier gauge jewelry often seen in GP.<sup>1,32</sup> Piercing removal kits designed by health care providers are available with accompanying educational materials.

Common GP jewelry are straight, curved, and circular barbells with threaded ends; one or both of the ends can

**Table 2.** Self-reported GP complications from three cross-sectional studies<sup>2,11,13</sup>

Complication	MGP (Caliendo et al, 2005) (n = 49)	MGP (Hogan et al, 2010) (n = 445)	WGP (Caliendo et al, 2005) (n = 35)	WGP Young et al, 2010 (n = 240)
NO problems	23 (47%)	209 (47%)	23 (65%)	153 (64%)
Urinary flow changes	19 (39%)	109 (25%)	—	—
Site sensitivity	15 (31%)	—	4 (11%)	—
Site hypersensitivity	—	101 (23%)	—	54 (23%)
Site hyposensitivity	—	7 (02%)	—	—
Skin irritation	9 (18%)	30 (07%)	2 (05%)	20 (08%)
Skin infections	4 (08%)	11 (03%)	1 (03%)	8 (03%)
Site rips or tears	4 (08%)	30 (07%)	—	—
Condom use problems	9 (18%)	24 (05%)	—	—
Birth control problems	1 (02%)	—	—	—
Oral sex problems	4 (08%)	—	—	—
Site keloids	4 (08%)	16 (04%)	1 (03%)	10 (04%)
Sexual problems	2 (04%)	4 (01%)	2 (05%)	1 (<1%)
Urinary tract infection	1 (02%)	7 (02%)	1 (03%)	3 (01%)
Embedded jewellery	—	4 (01%)	—	—
Erection problems	—	4 (01%)	—	—
Others, not named	2 (04%)	18 (04%)	1 (03%)	15 (06%)

be unscrewed, so while grasping one end, tighten the other end either to the right or loosen to the left.<sup>32</sup> Instituting an “exchange” technique<sup>32,33</sup> using the tip of an intravenous catheter (14 or 16 ga) without the needle, in the subcutaneous skin as a spacer for temporary removal of piercing jewelry, increases the patient’s confidence in the clinician’s concern for their GP.

**Complications With Genital Piercing.** Current complication rates for general body piercings range from 9-19%, with a 9% bacterial infection rate.<sup>18</sup> Especially in general body piercing review articles, much has been attributed to genital piercings, especially concerns of bleeding, infections, allergies, scarring, and keloid formation (Table 1).<sup>3,6,7</sup> WGP and MGP anonymously self-reported their GP complications (Table 2) with more than half (65%) of WGP and almost half (47%) of MGP reporting no problems. Those with Prince Albert rings (Table 2) had more urinary flow changes, whereas women had more hypersensitive site problems. To the best of our knowledge, Table 3 lists actual case history accounts (n = 17) from the peer-reviewed literature. An injury/bleeding instance among 7 GP subjects was also located, but no further information was provided<sup>18</sup> or included in Table 3. Overall, from both sets of data (Tables 2 and 3), WGP had fewer complications than MGP.

**Forensic Implications.** Situations could occur in an office or clinic when those with GP, especially WGP, present themselves as victims of abuse, neglect, and/or violence, or the piercings could become dislodged from physical assaults or even aggressive contact. Certainly approaching the GP individual in a nonjudgmental manner<sup>1,12</sup> is essential and forensic evidence collection should be delayed until the highest priorities of emergent care interventions are accomplished. Then, whether MGP or WGP are violated, the systematic principles of evidence collection, chain of custody, and documentation of forensic findings are important for any criminal

proceedings.<sup>1</sup> The area surrounding the jewelry and/or the piercing site could be part of the patient’s injuries so precision measurements of shape, appearance, and location, as well as patterned injuries, should be documented and the area swabbed for evidence to link victims, perpetrators, and crime scenes.<sup>1,11</sup> In addition, state, federal, and/or country regulatory requirements should be known, as well as the appropriate referrals for effective care continuity.

## COMMENT

Overall, there has been a moderate amount of body art literature. Yet, what was noted was that authors of some general body art articles, including discussion about GP, had a collective tendency to apply some of the complications from general body piercing sites onto GP, and other authors would replicate those concerns. Also, the GP literature seemed to be often clouded by potential concerns and uncited statements about MGP and WGP.<sup>3,5,9,11,19,30,35-40</sup> In addition, as the literature has provided evidence that those with tattoos and body piercings should be studied separately because of psychosocial differences, evidence presented here documents differences even within those who wear body piercings. Although there were some similarities, there were equally more differences in those with GP,<sup>2,3,6,8,11,13,15</sup> especially with psychosocial characteristics of age, gender, motivations, and deliberate procurement decision-making. More GP differences were found in legislative regulations, prevalence, procedural concerns, types of jewelry, after-care, and fewer overall complications. Further research to substantiate these differences will be important for clarity.

This review, almost 10 years after Anderson’s<sup>6</sup> thorough medical GP debut, provides further evidence about GP. Valuable data from this GP search included medical implications regarding the types, prevalence, technique, legislation, psychosocial perspectives, and procedural

**Table 3.** Published patient histories of GP complications (n = 17)

Reference	Complication	Type of GP	Location/Case History	Treatment/Outcome	Additional Comments
Esen and Orife (2006) <sup>41</sup>	Partner damage Postcoital bleeding	Prince Albert	(UK) 21 y F, 7 mo hx of postcoital injuries. Multiple deep & extensive vagina wall abrasions.	Colposcopic examination neg, cervical smear normal. Told to remove jewelry before intercourse.	Stressed effective education for GP wearers & partners.
Jones et al (2007) <sup>42</sup>	Postcoital bleeding	“partner had large ‘bar’ design, distal penile piercing”	(UK) 25 y F, 4 mo postcoital hx of bleeding 2-3 h after q intercourse. Severe dysuria, no STI	Examination showed urethra tear evidence w/bruising. With sexual abstinence, healing occurred.	Stressed good vulval & vaginal examinations. Abusive situation?
Das et al (2005) <sup>43</sup>	Loss of jewelry	Prince Albert	(UK) 20 y F concerned about bead dislodgement from partner’s piercing after oral sex.	Bead found lodged in intestine. No Rx. prescribed and subsequently passed bead	Stressed good sexual history for detection.
Ekelius et al (2004) <sup>22</sup>	Bacterial infection (local or systemic) Fournier’s gangrene	3 y old Prince Albert & 1 y old self-inflicted Ampallang piercing	(SW) 39 y M w/necrotizing fasciitis in genital track & perineum. “Daughter kicked him during sleep” admitted for pain relief.	Developed septicemia & DIC. Multiple antibiotic Rx. Hospitalization –43 d.	First case reported. Medical risks should not be underestimated.
Fiumara and Eisen (1983) <sup>25</sup>	<i>Mollusum contagiosum</i> (epidermotrophic pox virus)	Circular penile ring suspended from scar tissue of circumcision frenum	(US) 36 y M w/Hx of 3 mo lower abdominal “bumps.” Neg urethral STD Hx, pharyngitis & proctitis gonoccal +	Desiccation & curettage under topical refrigerant anesthesia. Lesions regressed spontaneously.	Suggested regular STD check for GP as a high risk group.
Pugatch et al (1998) <sup>26</sup>	Viral infection hepatitis B, C and HIV	Had multiple piercing sites, “including penis, scrotum,” otherwise GP type not identified	(US) 35 y admitted homosexual M. Piercings obtained national & international. “5 separate piercings might have used contaminated HIV needles for piercings”	22 mo after seroconversion to HIV, the patient was asymptomatic; no further information available.	Piercings potential route of HIV & bloodborne pathogen transmission, but further studies needed.
MacLeod and Adeniran (2004) <sup>44</sup>	Urethral fistula	Prince Albert	(UK) 35 y M had wider gauge Prince Albert ring inserted, created pain & edema. Piercing tract developed extensive fistula.	Appearance of acquired glanular hypospadias. No further discussion of Rx and outcome provided.	Pt later presented to plastic surgeon & urologists for reconstruction.
Kato et al (1987) <sup>21</sup>		Stainless steel ring (2 cm) on the base of the penis to prolong erection	(JA) 42 y M w/urinary retention due to penis strangulation. Self-inflicted piercing 1 mo previously. Gangrenous patches covered penis surface	To avoid amputation, used drill 2/diamond tip to sever ring-took 90 minutes, then area sutured, urethral fistula healed spontaneously at 66 PO day. All symptoms resolved.	English abstract & Japanese text.

Continued

**Table 3.** *Continued*

Reference	Complication	Type of GP	Location/Case History	Treatment/Outcome	Additional Comments
Slawik et al (1999) <sup>47</sup>	Bivalving urethra/ Urethral rupture	Prince Albert	(UK) 26 y (m) 6 mo post piercing had “frenzied passion” sexual intercourse & ring torn out.	Trauma produced glanular hypospadias, but then had penis repierced. No further information.	
Higgins et al (1995) <sup>46</sup>		Prince Albert	(UK) 43 y uncircumcized M, Hx 2 d painful urethral bleeding.	4 wk piercing partially avulsed, then removed by pt. STI & HBV neg. Rx. “surgical conservative”	MDs need more information on GPs.
Hall and Summerton (1997) <sup>45</sup>	Priapism	Prince Albert	(UK) 50 y M, after sexual stimulation presented w/deeply cyanosed & engorged penis. Pierced scrotal skin formed the constrictive band.	OR & band of scrotal skin was incised & penis relieved. Scrotal aperture was reconstructed. “Uneventful recovery”	
Jones and Flynn (1996) <sup>48</sup>	Paraphimosis	Prince Albert	(UK) 24 y M w/3 d hx penile pain following piercing.	Penile block & manual reduction. Resolved	
Hansen et al (1997) <sup>49</sup>		Ampallang	(DK) 24 y M w/swollen/painful penis, 4 d post piercing. Unable to replace retracted prepuce.	Penile block, piercing removed. 10 d later severe paraphimosis again & w/necrotic wounds. Partial foreskin excised. 2 mo later circumcision performed & Rx. for condylomas.	
Edlin et al (2010) <sup>50</sup>	Malignancies (squamous cell carcinoma, 2 cases)	Both Prince Albert	(US) 60 y M, hx of HIV & HCV, circumcised. Piercing 4 y old; pt removed piercing after painful intercourse & urine leakage 9 mo before admission. <sup>2</sup> (US) 56 y circumcised M w/Hx HIV, HCV w/1 episode of gross hematuria. Hx of piercing 15 y ago.	Now, w/urethra-cutaneous fistula (pT2NOM0). Partial penectomy & bilateral superficial lymphadectomy. <sup>2</sup> Multiple urethra fistulas, necrosis on penis (pT3NOM0). Partial penectomy & bilateral superficial lymph node dissection	MD believes site of origin was urethra due to history of GP, as causes focal & repetitive trauma to penis & urethra leading to chronic inflammation.

*Continued*



**Table 3. Continued**

Reference	Complication	Type of GP	Location/Case History	Treatment/Outcome	Additional Comments
Altman and Mangiani (1997) <sup>51</sup>	Recurrent condyloma acuminata	Ampallang	(US) 22 y M with 5 mm verrucal papule protruding from dermal linear tubular scar on penile frenulum. Hx papillomavirus infection.	Rx. w liquid nitrogen & podophyllin. Verruca and pierced hole with the overlying skin were excised.	MD advocates waiting period before piercing decision & procedure.
Hounsfeld and Davies (2008) <sup>27</sup>	Chlamydial and gonococcal infection of the urethra	Prince Albert (reverse)	(AU) 26 y M, heterosexual, previous ring 3 y old, replaced it & 2 d later w/urethral discharge, dysuria, & penile edema. Also genital warts. + Culture chlamydial & gonococcal.	Ceftriaxone IM & azithromycin RX; warts treated w/cryotherapy 1x. Symptoms resolved	Suggest thorough sexual history-taking & consideration of unusual routes of transmission of infection.

concerns. Although urologists usually encounter patients presenting with problematic situations, and one would expect a plethora of GP concerns, the complication evidence of 17 cases over 17 years seems limited, and often relevant GP information was not included to determine whether it really was a problem with the GP; 75% of the cases were from international sources,<sup>21,22,27,41-49</sup> with more than half (65%) of Prince Albert piercings.<sup>22,27,41-49,50</sup> Before 2000, 9 cases were published<sup>21,25,26,45-49,51</sup> and 8 after 2000,<sup>22,27,41-44,50</sup> along with peer-reviewed literature from self-reported data.<sup>2,11,13,15</sup> The current literature has surprisingly yielded little documented research and complications, while challenging more assumptions typically applied to GP wearers. Thus, further published interventional data about GP experiences, with or without complications, especially jewelry removal or nonremoval and adequate visualization during diagnostic procedures, will be important as the popularity of GP continues and theoretically intensifies the percentage of urology encounters. Currently, the health care literature is virtually the only source for piercing complications because there is no national tracking to monitor body art problems,<sup>4</sup> although the state of Rhode Island has attempted some reporting. An international electronic database<sup>6,11,13</sup> would provide a better repository.

GP complications seem to arise from 4 areas: (1) poor technique during procurement<sup>21,27,44,48</sup>; (2) lack of effective, conscientious GP after-care<sup>21,22,45,46,49</sup>; (3) body changes after long-term jewelry wear<sup>25,47,50-51</sup>; and/or (4) partner damage.<sup>41-43</sup> Although both genders procure and possess GP, more procedural concerns seem to apply to the various male styles,<sup>2,13</sup> whereas WGP tend to provide more rationale.<sup>11,13,15</sup> Both site sensitivity and hypersensitivity (Table 2) were self-reported problems from WGP and MGP,<sup>2,11,13</sup> but no questions asked for more details; further research would be helpful for better clarity and resolution of this phenomenon. Other data has suggested carcinoma<sup>50</sup> occurring from the presence of repetitive GP trauma, as well as oncogenic properties from stainless steel jewelry, "altering the signal transduction of growth factor receptors."

With any invasive procedure, HBV, HCV, and HIV are always potential concerns and the possibility will continue with individual risks and hygiene practices.<sup>6,8,27,50-51</sup> Yet, for those with GP, few actual cases of HBV, HCV, and HIV were located.<sup>26,50,51</sup> To further substantiate a relationship, more longitudinal analysis will need to be done before and after body art procurement to adequately rule out other risk variables. Also, contrary to the many STI assumptions with those wearing GP, limited documentation is present.<sup>2,11,13,27</sup> One theory raised is the presence of an antibacterial effect in males with a slow release of metal ions from the Prince Albert piercing when their female sexual partners tested positive for chlamydia.<sup>6,12</sup> In addition, sexual orientation of those with GP has been questioned but there is currently still mixed evidence.<sup>2,11,13,29-30</sup>

Regardless of whether clinicians agree with the practice of GP,<sup>2,4,6</sup> it is part of the wearers' cultural expression.<sup>32</sup> Realistically, if GP wearers regretted their decision, they could readily remove the piercings.<sup>11,13</sup> Even those with Prince Albert piercings do not seem deterred with urinary flow changes.<sup>2</sup> From this review, GP are of value to them as a meaningful part of their lives that enhances their sexual satisfaction and helps them with sexual self-expression,<sup>2,8,10,11,13</sup> and because of that, most take very good care of their GP.<sup>2,11,13</sup> Culturally sensitive care perspectives,<sup>1,4,10,32</sup> gathering further GP knowledge, and striving to provide the best evidence-based medical care to MGP and WGP will further their seeking of health care advice and interventions from medical professionals.

**Acknowledgments.** The authors acknowledge the support of Bernhard T. Mittermeyer, M.D., Emeritus, Urology, School of Medicine, and the services of Larry Starr, Senior Design Specialist, Texas Tech University Health Sciences Center, Lubbock, Texas.

## References

1. Halliday KA. Body piercing: issues and challenges for nurses. *J Forens Nurs.* 2005;1(2):47-56.
2. Hogan L, Rinard K, Young C, et al. A cross-sectional study of men with genital piercings. *Br J Med Pract.* 2010;3(2):315-322.
3. Stirn A. Body piercing: medical consequences and psychological motivations. *Lancet.* 2003;361(9364):1205-1215.
4. Armstrong ML, Koch JR, Saunders JC, et al. The hole picture: risks, decision making, purpose, regulations, and the future of body piercing. *Clin Dermatol.* 2007;25:398-406.
5. Meltzer DI. Complications of body piercing. *Am Fam Physician.* 2005;72:2029-2034.
6. Anderson WR, Summerton DJ, Sharma DM, et al. Andrology: the urologist's guide to genital piercing. *Br J Urol.* 2003;91:245-251.
7. Angel E. *The Piercing Bible: The Definitive Guide to Safe Body Piercing.* Berkeley, CA: Crossing Publishing Group; 2009.
8. Ferguson H. Body piercing. *BMJ.* 1999;319:1627-1630.
9. Stewart C. Body piercing: dangerous decoration. *Emerg Med.* 2000; 32:92-98.
10. Van der Meer GT, Weijmar-Schultz WCM, Nijman JM. Intimate body piercings in women. *J Psychosom Ob Gyne.* 2008;29(4):235-239.
11. Young C, Armstrong ML, Mello I, et al. A triad of evidence for care of women with genital piercings. *J Am Acad NP.* 2010;22(2):70-80.
12. Tweeten SS, Rickman LS. Infectious complications of body piercing. *Clin Infect Dis.* 1998;26:735-740.
13. Caliendo C, Armstrong ML, Roberts AE. Self-reported characteristics of women and men with intimate body piercings. *J Adv Nurs.* 2005;49:474-484.
14. Khanna R, Kumar SS, Raju BS, et al. Body piercing in the accident and emergency department. *J Accid Emerg Med.* 1999;16:418-421.
15. Koch JR, Roberts AE, Armstrong ML, et al. Body art, deviance, and American College students. *Soc Sci J.* 2010;47(1):151-161.
16. Taylor P, Keeter S. Pew Research Center: Millennials: A Portrait of Generation Next. 2010. Available at: <http://pewresearch.org/millennials>. Accessed February 28, 2011.
17. Laumann AE, Derick AJ. Tattoos and body piercings in the United States: a national data set. *J Am Acad Dermatol.* 2007;55(3):413-421.
18. Mayers LB, Judelson DA, Moriarty BW, et al. Prevalence of body art (body piercing and tattooing) in university undergraduates and incidence of medical complications. *Mayo Clin Proc.* 2002;77: 29-34.

19. Millner VS, Eichold BH, Sharpe TH, et al. First glimpse of the functional benefits of Clitoral Hood piercings. *Am J Obstet Gynecol.* 2005;193:675-676.
20. Lehmann J, Jancke C, Retz M, et al. A hypoechoic lesion found on testicular ultrasound after testicular piercing. *J Urol.* 2000;164(5): 1651.
21. Kato Y, Kaneko S, Igucki M, et al. Strangulation of the penis by a ring. *Hinyoikka Kiyo.* 1987;33:1672-1675.
22. Ekelius L. Fournier's gangrene after Genital Piercing. *Scand J Infect Dis.* 2004;26:610-612.
23. Zermann DH, Schubert J. Strangulation of the scrotum. *Scand J Urol Nephrol.* 1997;31:401-412.
24. Goldman M, Xi G, Yi QL, et al. Reassessment of deferrals for tattooing and piercing. *Transfusion.* 2009;49:648-654.
25. Fiumara NJ, Eisen R. The titivating penile ring. *Sex Transm Dis.* 1983;10:43-44.
26. Pugatch D, Mileno M, Rich JD. Possible transmission of human immunodeficiency virus type 1 from body piercing. *Clin Infect Dis.* 1998;26:767-768.
27. Hounsfeld V, Davies SC. Genital piercing in association with gonorrhoea, chlamydia and warts. *Int J STD AIDS.* 2008;19:499-500.
28. Alan Guttmacher Institute. Sexual and Reproductive Health: Women and Men. 2002. Available at: [http://www.guttmacher.org/pubs/fb\\_10-02.html](http://www.guttmacher.org/pubs/fb_10-02.html).
29. Willmott FE. Body piercing: lifestyle indicator or fashion accessory? *Int J STD AIDS.* 2001;12:358-360.
30. Miller L, Edenholt M. Genital piercing to enhance sexual satisfaction. *Obstet Gynecol.* 1999;93(5):837.

## APPENDIX

### SUPPLEMENTARY DATA

Supplementary data associated with this article can be found, in the online version, at doi:10.1016/j.urology.2011.05.066.

## EDITORIAL COMMENT

The authors present what is certainly the most comprehensive review to date of genital piercings (GPs) and have provided an invaluable resource for any urologist that encounters GPs in their practice.

I am as guilty as the next urologist when it comes to managing GPs. If I encounter one in my practice, especially when it obstructs performing a study or urinary flow, or it leads to some other type of urological problem, I tell the patient to take it out. However, this kind of attitude may be exactly what leads these patients to seek non-health care professional help for GP issues. They do not want to take them out. They come to us to tell them how they can keep them in.

Perhaps it is time that we begin to accept the new reality of GPs in the "Facebook" era, where individuality is everything and GPs feed the need to stand out among the ever-expanding crowd. Our colleagues in dentistry and otolaryngology have dealt with piercing issues for some time<sup>1</sup> and have collectively figured out methods to work with them. We must begin to do the same in the urological community if we are ever to understand the epidemiology of GPs and, more importantly, create an evidence-based approach to managing their associated complications while keeping the patients' wishes and desires in mind. This manuscript is a big step in the right direction.

**Bradley A. Erickson, M.D.,** Department of Urology, Carver College of Medicine, University of Iowa, Iowa City, IA